*Journal of Indian Academy of Obstetrics and Gynaecology* July 2023
Vol. 5, Issue 1

**Case Report**

# A MISTAKEN CASE OF HYDATIDIFORM MOLE

**Nilakshi Phukan Kumar[1]✉, Subhendu Buzarbaruah[1]**

**ABSTRACT**

This is a case of recurrent hydatidiform mole in 30-year-old women. Initially diagnosed with a molar pregnancy in September 2020, underwent D&E and received methotrexate treatment, resulting in a decline of beta hCG levels to 0.8mIU/ml by December 2020. Subsequent ultrasound in March 2021 indicated a hydatidiform mole like picture despite of low beta hCG (<2.0mIU/ml). An MRI suggested similar findings without myometrial invasion, without enlarged lymph nodes or ascites. Histopathology of D&E sample showed endometrial hyperplasia rather than hydatidiform mole. Upon detailed history review, it was found the patient had been self-administering mifepristone at 25mg/day for over five months post the initial procedure. Literature search links extended high dose mifepristone usage to an unopposed estrogen environment, causes endometrial hyperplasia, alerting us to monitor prolonged mifepristone use meticulously.

**Key words**: Hydatidiform mole, Molar pregnancy, prolonged mifepristone

## INTRODUCTION

A 30-year-old female patient was referred to down town hospital in March 2021 with a diagnosis of recurrent hydatidiform mole. In January 2019 she had a failed IVF following blastocyst transfer. Subsequently she had a spontaneous pregnancy in September 2020 later diagnosed to be a molar pregnancy with a beta human chorionic gonadotrophin (hcg) of about 85,000 mIU/ml. A dilatation and evacuation were performed and she received a full course of methotrexate and folinic acid in September 2020. Following this, her beta hcg dropped to 16.8 mIU/ml in October 2020. Beta hgc further decreased to 0.8 mIU/ml in December 2020. A histopathology revealed hypersecretory endometrium with extensive decidualization of stroma with focal areas of areas Stella reaction. No chorionic villi were identified. There was no evidence of hydatidiform mole.

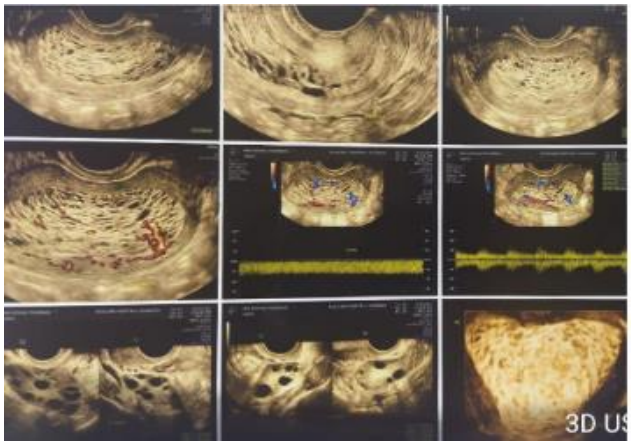

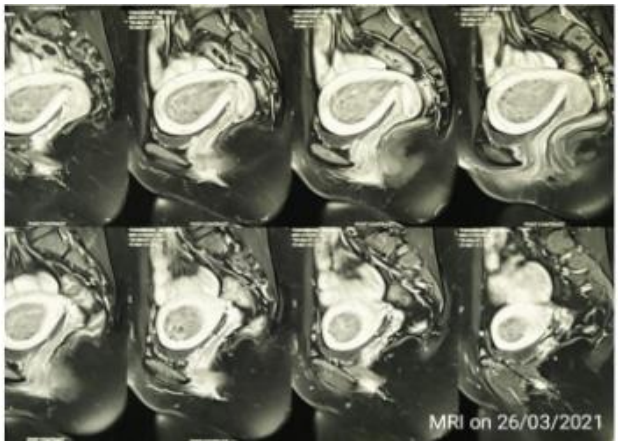


Fig 1 & Fig 2: Ultrasonography and MRI reveal features suggestive of hydatidiform mole in March 2021

**DIAGNOSIS AND MANAGEMENT**

The same patient came to down town hospital with a hydatidiform mole like picture shown in ultrasound done in March 2021 with a beta hcg level of <2.0 mIU/ml. An MRI done in March 2021 revealed features suggestive of hydatidiform mole without invasion of inner myometrium, without enlarged lymph nodes or ascites.

A dilatation and evacuation were done in April 2021 at our hospital under ultrasound guidance. The endometrial tissue was evacuated but no typical grape like tissues identified. The material retrieved was sent for hystopathological (HPE) examination. The HPE revealed secretory hyperplasia of endometrium with no evidence of hydatidiform mole. Subsequently the patient recovered with no clinical or laboratory findings of hydatidiform mole.

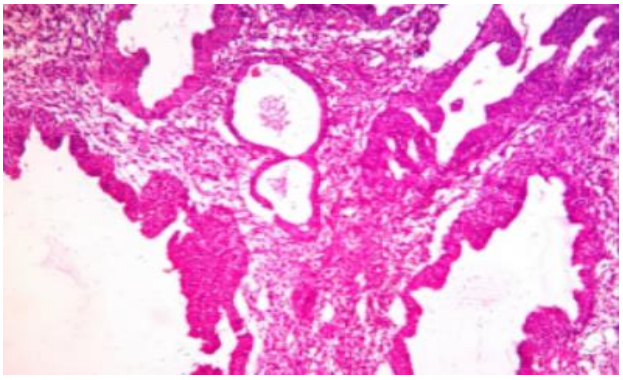
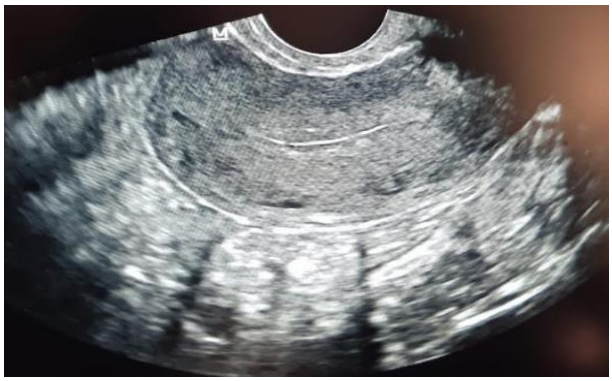

Fig 3: HPE revealed secretory endometrium without atypia in April 2021 Fig 4: Ultrasonography showing normal endometrium in May 2021

**DISCUSSION**

On obtaining detailed history, it was revealed that the patient was advised mifepristone 25 mg/day following the dilatation and evacuation performed in September 2020 for an unspecified indication. The patient didn't follow-up with the treating gynaecologist and continued taking mifepristone 25 mg/day for a period of more than 5 months. A literature search revealed case reports that showed high doses of the antiprogestogen mifepristone over a prolonged period of time may promote an unopposed oestrogen milieu leading to endometrial hyperplasia.[1]

## CONCLUSION

Diagnosis of hydatidiform mole should not be based only on ultrasound findings and needs to be correlated with the level of hcg level as well as histopathological findings. Prolonged use of mifepristone should be monitored as an unopposed oestrogen milieu may lead to endometrial hyperplasia. Further studies are required to rule out the role of prolonged use of mifepristone in endometrial hyperplasia.

## REFERENCE

1. Newfield RS, Spitz IM, Isacson C, New MI. Long-term mifepristone (RU486) therapy resulting in massive benign endometrial hyperplasia. Clin Endocrinol (Oxf). 2001;54(3):399-404.

*Received:* 25.05.2023
*Revised:* 11.06.2023
*Accepted:* 14.06.2023
*Published:* 15.07.2023
*Citation:* Kumar NP, Buzarbaruah S. A mistaken case of Hydatidiform mole. J Indian Acad Obstet Gynaecol. 2023;5(1): page no.

1. Consultant, OB-GYN, Down Town Hospital, Guwahati, Assam

✉ Email: nilakshi.phukhan@yahoo.co.in